



Corneal Transplantation –

Indications and Current Techniques



Associate Professor Graham A Lee MD MBBS FRANZCO

Dr Katie Chen MBBS



Corneal transplantation, also known as corneal grafting or keratoplasty is a procedure during which dysfunctional cornea is removed from a patient's eye and replaced with healthy clear cornea from a donor. Since the first successful human corneal graft by Dr Eduard Zirm in 1905, corneal transplantation knowledge, practice and technology have advanced rapidly. Today, with the establishment of eye banks, it is the most commonly performed and successful transplant surgery.

Corneal Anatomy

The cornea functions to transmit and focus light together with the lens, onto the retina. It also has a protective function shielding against foreign bodies and infection as well as filtering UV radiation. The cornea is made up of five layers each with important functions, with a normal thickness of approximately 550µm centrally and 650µm peripherally.

1. Epithelium (50µm): outermost layer of the cornea, approximately 5-6 layers thick of non-keratinised stratified squamous cells.
2. Bowman's Layer (10µm): acellular layer of homogenous collagen fibres directly under the epithelium.
3. Stroma (450-500µm): regularly arranged lamellae of collagen bundles. The arrangement of the collagen achieves a strong, elastic, clear structure that is capable of transmitting light.
4. Descemet's membrane (12µm): thin but tough basal lamina of the endothelium.
5. Endothelium (10µm): innermost layer of the cornea consisting of a single layer of cuboidal cells. The endothelium is functionally vital to maintain corneal clarity by maintaining relative fluid balance. Endothelial cells do not regenerate and once they are lost from disease or trauma, the only available treatment is corneal transplantation.

Indications for Corneal Transplantation

- ▶ Optical/refractive: to improve visual acuity due to opacification of the cornea or disruption of its structure.
- ▶ Tectonic/reconstructive: to maintain corneal anatomy and integrity.
- ▶ Therapeutic: as treatment for infective keratitis that is refractory to antibiotics or antifungals.
- ▶ Cosmetic: to improve the appearance of eyes with opaque corneal scarring.

Eye Conditions

The most common reason for a corneal transplant in Australia is keratoconus, followed by bullous keratopathy, failed previous transplant, Fuch's endothelial dystrophy, herpetic eye disease, corneal scarring and trauma.

- ▶ Keratoconus: a degenerative disorder of the eye where the cornea progressively assumes an irregular conical shape rather than a regular curvature (Figure 1). Keratoconus causes significant visual distortions with often asymmetrical progressive myopia (short-sightedness) and astigmatism (abnormal curvature). Patients may initially report frequent changes in spectacle prescription or intolerance to contact lens wear. Marked corneal thinning of the central and paracentral stroma can lead to rupture of Descemet's membrane and an acute influx of aqueous into the cornea (acute hydrops) (Figure 2).



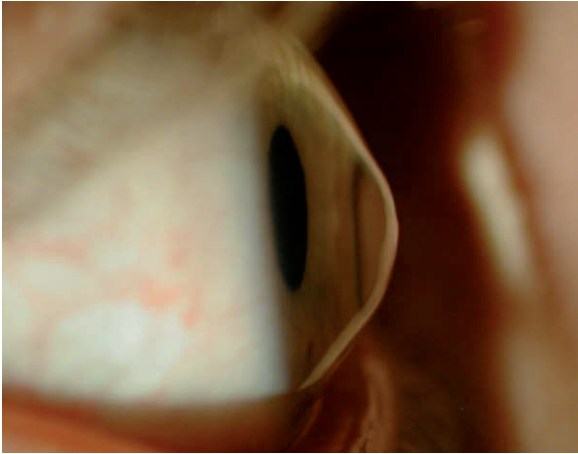

Figure 1. Keratoconus

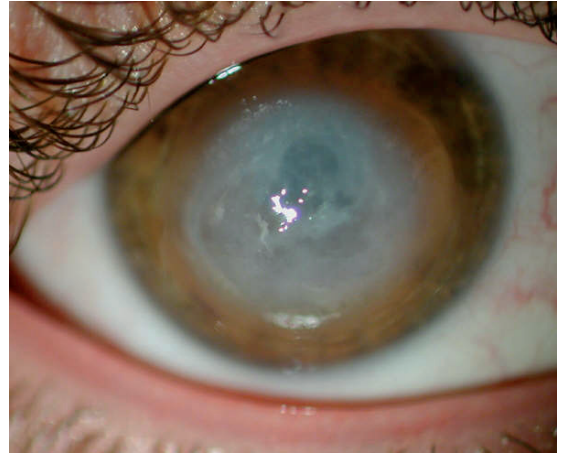


Figure 2. Acute hydrops

- ▶ Bullous keratopathy: swelling of the cornea secondary to either traumatic or degenerative endothelium dysfunction (Figure 3). The swelling can lead to fluid filled blisters forming on the surface of the cornea impairing vision and eye pain. Bullous keratopathy is associated with complicated eye surgery due to direct endothelial damage or anterior chamber intraocular lens.

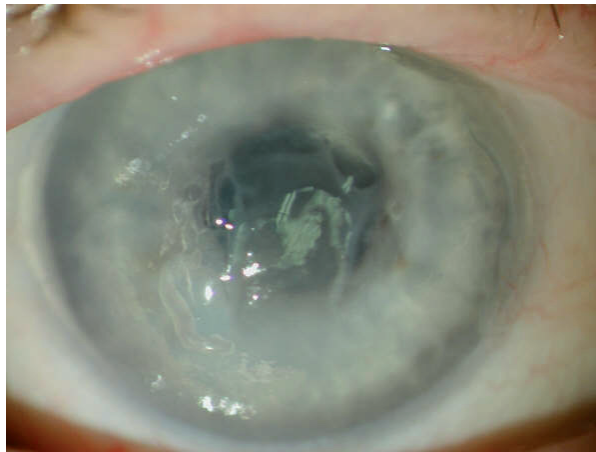


Figure 3. Bullous keratopathy

- ▶ Corneal dystrophies: a group of diseases which are progressive, non-inflammatory, cornea opacifying and usually bilateral. Most of the dystrophies are genetically determined.
 - Fuch's endothelial dystrophy- progressive loss of endothelial cells faster than the usual age degeneration (Figure 4). Patients complain of blurred vision that is

initially worse in the morning and clears later in the day. However, as the disease progresses, the persistent epithelial oedema can result in loss of vision and pain due to bullous keratopathy.

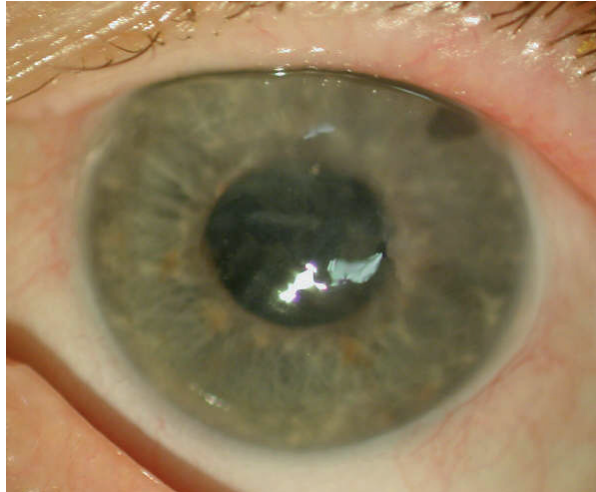

Figure 4. Fuch's endothelial dystrophy

- Stromal dystrophy- a group of hereditary dystrophies in which there is an accumulation of deposits throughout the anterior and middle stroma causing opacities in varying shapes (Figure 5). Over time the opacities become denser causing progressive vision impairment.

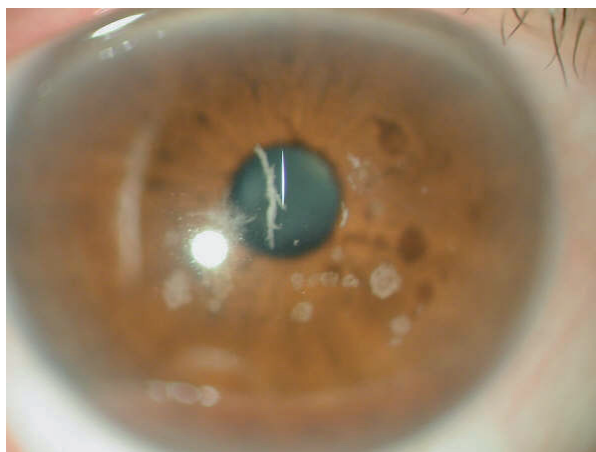


Figure 5. Stromal (Avellino) Dystrophy

- Herpetic eye disease- corneal scarring as a result of recurrent infection from the herpes simplex virus

(Figure 6) and less frequently from herpes zoster involving the ophthalmic division of the trigeminal nerve. There are a variety of presentations ranging from corneal scarring, vascularisation, ulceration and even perforation of the cornea.

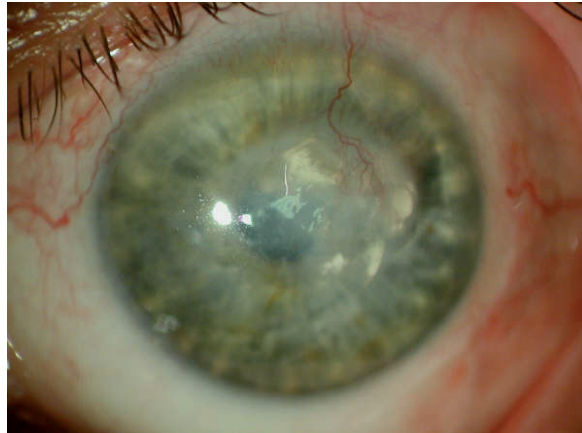


Figure 6. Herpetic corneal scarring

Recent Developments in Corneal Transplantation

Over the past decade, lamellar keratoplasty (LK) or partial thickness corneal grafting has emerged as the principle alternative to penetrating keratoplasty (PK) or full thickness corneal grafting. LK involves a targeted removal of diseased cornea and replacement with healthy donor cornea, whilst preserving the unaffected layers.

Partial thickness corneal grafting can involve replacing either the anterior stroma (anterior lamellar keratoplasty [ALK]) (Figure 7) or the posterior stromal and endothelial layers (posterior lamellar keratoplasty [PLK] or endothelial keratoplasty [EK]) (Figure 8).

ALK – Anterior lamellar keratoplasty

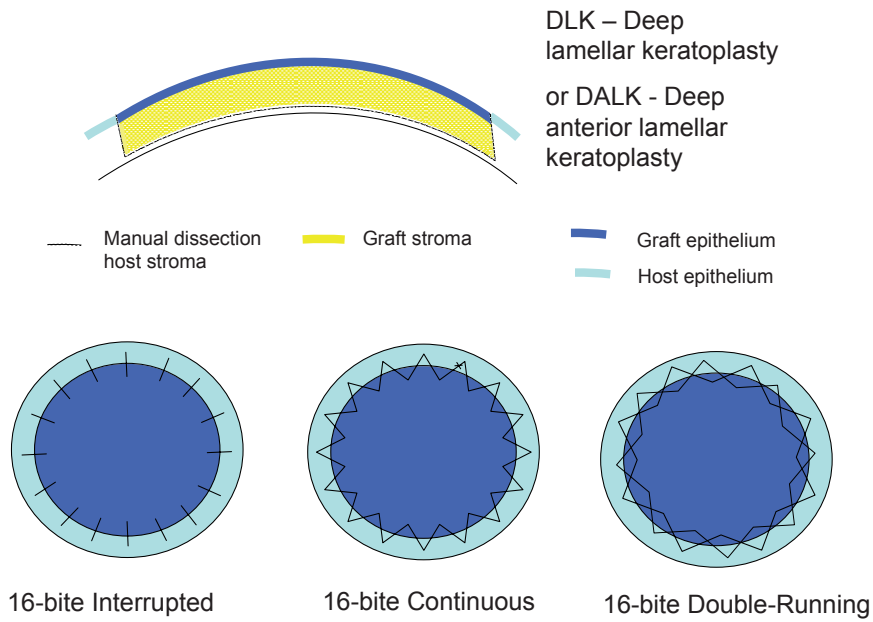


Figure 7. Anterior lamellar keratoplasty (ALK) and suturing techniques

PLK – Posterior lamellar keratoplasty

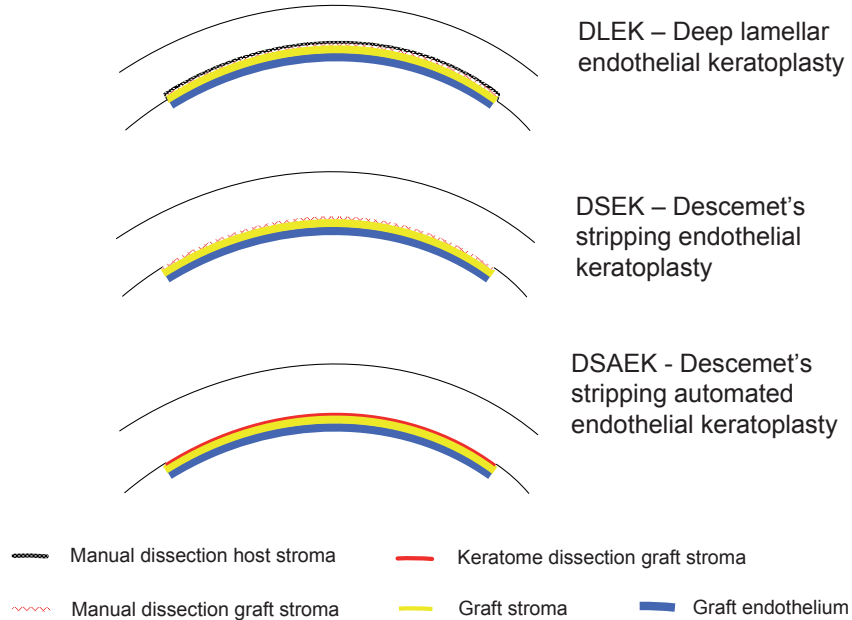


Figure 8. Posterior lamellar keratoplasty (PLK)



In diseases such as keratoconus, the healthy endothelium can be preserved with ALK techniques - deep lamellar keratoplasty (DLK) or deep anterior lamellar keratoplasty (DALK). Having an intact recipient endothelial layer eliminates endothelial rejection and long term failure is unlikely. Being mostly a non-penetrating procedure, the incidence of intraocular complications such as glaucoma, cataract formation, retinal detachment and endophthalmitis are greatly reduced. The eye is tectonically stronger than following a penetrating keratoplasty as Descemet's membrane is not breached.

There are a multitude of acronyms associated with PLK (Figure 8). The more common terminologies are:

- ▶ DLEK (deep lamellar endothelial keratoplasty) where the donor lamella and the host cornea are hand-dissected.
- ▶ DSEK (Descemet's stripping endothelial keratoplasty) where the host endothelium is peeled off and the hand cut donor lamella is attached.
- ▶ DSAEK (Descemet's stripping automated endothelial keratoplasty) where the host endothelium is peeled off and the automated keratome cuts the donor lamella graft.

Endothelial keratoplasty has faster visual rehabilitation in terms of visual acuity, stability of refraction and less astigmatism compared to PK. Risk of rejection is also less as there is minimal donor tissue transplanted. The absence of graft sutures also reduces the risks of wound dehiscence and infectious keratitis. There is no full-thickness cut, so that the eye is tectonically stronger and less prone to injuries compared to PK. The rate of loss of endothelial cells is similar to penetrating keratoplasty. The procedure is more technically challenging than a penetrating keratoplasty and graft dislocation rates occur in 5-10%; these patients then require re-positioning of the graft or conversion to a PK.



The Procedure

Corneal grafting is usually performed as a day procedure under local anaesthesia with sedation. A general anaesthesia is sometimes used, particularly in children and if the patient is uncooperative, or if it is the surgeon's preference.

The procedure takes approximately 40-60 minutes, sometimes longer for complex cases or in combined procedures such as with cataract removal. The aim is to remove the abnormal tissue whilst maximally preserving normal tissue. In ALK, a trephination is made at around 90% depth and the deep stroma dissected manually to retain the Descemet's membrane and endothelium. The donor graft is placed onto the stromal bed and sutured into place with 10/0 Nylon, either in a continuous or interrupted suture pattern (Figure 9). In PLK, the endothelium and Descemet's membrane are dissected or stripped off the posterior stroma. The donor graft is harvested on an artificial anterior chamber and the delicate Descemet's membrane and endothelium positioned onto the posterior host stroma with the aid of an air bubble. The patient then needs to lie flat for the first 48 hours to keep the bubble in the correct position. There is progressive clearing of the cornea over the first few months (Figure 10).

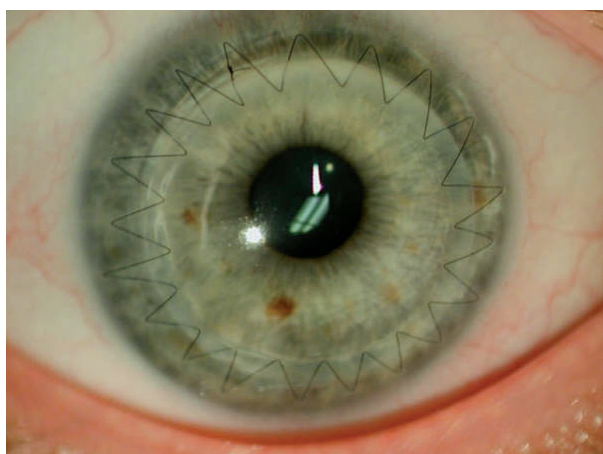


Figure 9. Deep lamellar keratoplasty (DLK) with continuous suture

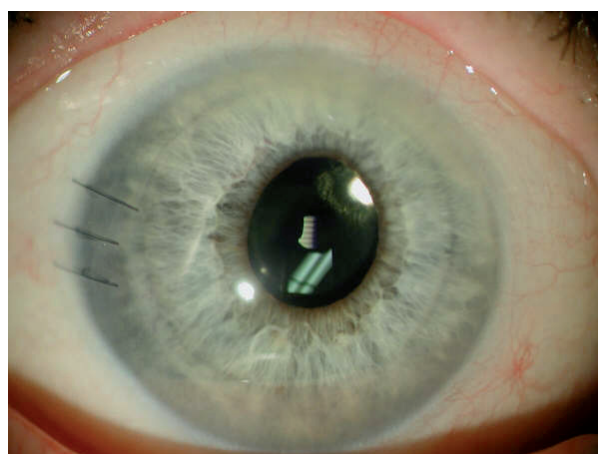


Figure 10. Descemet's stripping endothelial keratoplasty (DSEK)



Post-op Care

An eye pad and shield are applied overnight and the eye checked the next morning. The eye does not need further bandaging, however the patient is instructed to wear dark glasses whilst outdoors. Eye drops in the form of antibiotics and steroids are given for the first 3-6 months or longer in complex cases. Heavy lifting (>20kg) or bending over should be avoided in the first 2 weeks. Hair washing with closed eyes is permitted. Most patients require 1-2 weeks off work.

In ALK, the stitches remain in situ until the graft-host junction has healed which is usually 9-12 months after the operation and in some cases, are left in long term, dependent on the corneal shape and healing. The sutures are buried and do not usually cause foreign body sensation. If this occurs the patient must be referred for a review by an ophthalmologist within 24 hours for the removal of the suture.

The visual recovery after traditional PK is over 12-18 months. The aim in the first 3 months is mainly to make sure the graft is healing well and to prevent rejection. After the initial period, glasses or contact lenses can be prescribed to help improve vision, however the final vision won't be known until the sutures are removed in 12-18 months. Residual astigmatism can be further corrected by relaxing incisions/ re-suturing or excimer laser.

Graft Rejection

Graft rejection is a potential complication for any donor tissue (Figure 11); however, as the cornea is avascular, it has an immune privilege with a low rejection rate. Rejection can occur at any time from two weeks, however is more common in the first two years. Patients may complain of decreased vision, redness, pain, irritation, discharge and/or photophobia. Fortunately, corneal graft rejection if recognised and treated aggressively with topical steroids can be reversed. Any corneal graft patient with the above symptoms lasting more than a few hours should be instructed to seek urgent ophthalmologic attention.

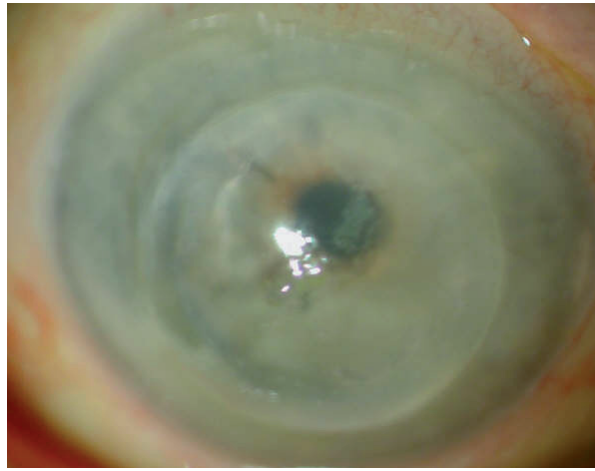


Figure 11. Corneal graft rejection

Conclusion

Currently more than 18,500 transplant recipients are on the Australian Corneal Graft Registry since its inception in 1985. It is important to have an understanding of the indications for surgery, techniques available, post-operative care and potential complications of corneal transplantation so that optimal outcomes are achieved for the patient.

Main Points

- ▶ Modern corneal transplant techniques are aimed at replacing only the diseased tissue
- ▶ Anterior lamellar techniques are used in diseases where the endothelium is normal, ie keratoconus, anterior stromal scarring
- ▶ Posterior lamellar techniques replace the abnormal endothelium whilst preserving the stroma and epithelium, eg Fuch's endothelial dystrophy, post-surgical trauma
- ▶ Penetrating keratoplasty is still required if there is significant anterior stromal scarring and abnormal endothelium
- ▶ Modern techniques are associated with more rapid visual recovery, less risks of rejection and a tectonically stronger eye compared to penetrating keratoplasty
- ▶ Any corneal graft patient with decreased vision, redness, pain, irritation, discharge and/or photophobia needs to be urgently referred for ophthalmological review of possible rejection